

Dysprosody in Three Patients with Vascular Cerebral Damage

Lourdes Pietrosevoli, Elsa Mora

Universidad de Los Andes. Mérida, Venezuela
Centro de Investigación y Atención Lingüística (CIAL)
lou_delvalle@yahoo.com; elsamora@icnet.com.ve

Abstract

The data on the neurological bases of prosody are apparently contradictory. This has led to the postulation of four different hypotheses about the cerebral organization of prosody. In the present study the rhythm and melodic contours of spontaneous speech are analyzed for two patients with vascular damage in the right hemisphere and for one in the left hemisphere. The acoustic analysis demonstrated some prosodic problems with relation to intonation but more with rhythm. These data reinforce the hypothesis of bilateral control of prosody and suggest the intervention of sub-cortical areas. They also contribute to the rejection of the organizational model of prosody in the right hemisphere as parallel to the linguistic organization in the left hemisphere.

1. Introduction

The studies on the neurological bases of the prosodic abilities have presented apparently contradictory results. Some of them will be briefly discussed. Blumstein and Cooper 1974 [2], for example, on the basis of experiments of dichotic listening, propose that there is right lateralization of the intonation contours of the voice. To quote:

“Results from the two experiments suggest that the right hemisphere is directly involved in the perception of intonation contours”

Nonetheless, Emmorey, in Fromkin 1988 [5] shows cases of patients with a lesion in the left hemisphere who have difficulties in the differentiation of simple words with two prosodic stresses (bláck and bóard are two of the examples cited), and compound words with only one prosodic stress (bláckboard, for example). This type of experiment leads Fromkin 1988 [5], in a revision of the relationship between brain and language, to propose the following:

“the processing of linguistic prosody, determined by the grammar, is thus a function of the left hemisphere, whereas affective prosody appears to be processed by the right hemisphere.”

This dichotomy between linguistic prosody/affective prosody has become popular and has been mainly supported by Ross and his colleagues (Ross, 1981 [7]; Ross and Mesulam, 1979 [8]), who claim that the right hemisphere is “in charge” of all aspects of affective and emotional prosody. Ross 1981 explicitly proposes that prosody is organized in the right hemisphere as a mirror image of the non-prosodic linguistic functions in the left hemisphere. Thus the right anterior region would control the production of prosody, while the right posterior areas would control prosodic interpretation or comprehension. However, up till now there

have not been sufficient arguments to confirm Ross’s hypotheses about the anterior/posterior division of prosody in the right hemisphere. Bradvik, Dravins, et al 1991 [3], for example, question Ross’s “zonal” prosodic scheme and report a study of 20 patients with cortical and sub-cortical damage in different regions of the right hemisphere who showed loss of linguistic prosody as well as loss of affective and emotional prosody. In their own words:

“It was not possible to find support for the hypothesis that the organization of prosody in the right hemisphere mirrors that of propositional speech on the left side.”

It is important to add to this discussion a comprehensive revision of research on the neurological bases of prosody based on studies of lesions and neuroimaging presented by Baum and Pell (1999) [1], who found four principal hypotheses: a) All prosodic aspects of speech are attached to cortical areas of the right hemisphere and are integrated with other linguistic aspects of speech through the corpus callosum (Klouda et al. 1998 [6], for example). b) Only the affective and emotional aspects of prosody are related to cortical areas of the right hemisphere; the linguistic aspects of prosody would be processed by cortical areas of the left hemisphere (Van Lancker, 1980 [9]). c) All aspects of prosody are processed in sub-cortical areas (Cancelliere and Kertesz, 1990 [4]). d) The acoustic cues for prosody could be lateralized independently (Van Lancker and Sidtis, 1992 [10]).

As we can see, up to now the data that have been collected for the study of the neurological bases of prosody are not uniform, nor are the conclusions, since there is research that seems to equally support the different hypotheses found by Baum and Pell 1999 [1].

The purpose of our research is to contribute to the discussion with an acoustic analysis of the prosody of conversational Spanish in three patients with vascular cerebral lesions.

2. The Study

2.1. The cases

The cases of dysprosody studied were of three patients, two women and one man, who had suffered vascular cerebral accidents. A neurological description based on Nuclear Magnetic Resonance follows:

Case 1 (ML: female, 42): A cavitation in the right frontal-parietal region with extension into the white periventricular matter. The left and right temporal lobules are intact.

Case 2 (LL: male, 47) Zone of encephalomalasia at the left temporal-parietal level. Retraction of the left lateral ventricle in relation with the zone of encephalomalasia.

Case 3 (CR: female, 45) Right cavitation in the temporal region with lower parietal extension. The cavitation was observed to have a notable extension on the vertical axis in the zone of the infarction.

2.2. Linguistic data

The data come from recordings of quasi-informal conversations between the above-mentioned patients and their therapist. The recordings of the speakers' voices were digitalized and analyzed in the CSL 4300. Intonation and rhythm were the prosodic elements analyzed. The analysis started with the reading of the values of the fundamental frequency and length of syllables in the utterances selected for this study. These utterances were the ones where the speakers expressed themselves with greater fluency.

In the next section we present the graphics, which schematize the acoustic analysis of the syllables of each one of the phrases selected from the individual patient's conversations. The figures correspond to an example of the predominant tendency in the emissions of each of the patients.

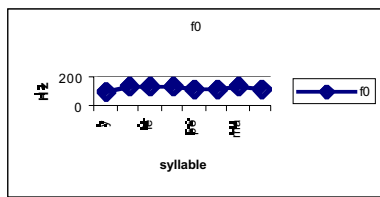


Figure 1. Analysis of the intonation of a declarative phrase produced by the patient ML. (Phrase: Y me enfermé por esa semana.)

Case 1, ML: As can be observed in Figure 1, the intonation of the phrase begins with a sudden rise of fundamental frequency to continue with a line that is quite flat at the same height and, as a result, little melodic variation.

In contrast, the speech rhythm of the same patient is characterized by the presence of frequent pauses, including within words. At the same time there are syllables that are very long in contrast with ones that are short, as may be observed in figure 2.

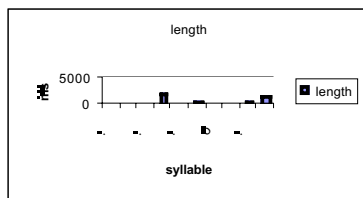


Figure 2. Analysis of the rhythm in a phrase produced by the patient ML. (Phrase: Por (pause) que (pause) porque yo vine (pause)).

In figure 3 we present the analysis of the intonation of a declarative phrase produced by the patient LL.

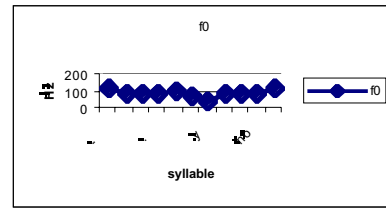


Figure 3. Analysis of the intonation in the speech produced by the patient LL. (Phrase: Bueno hay mayores y hay menores).

Case 2, LL: We observe in figure 3 that the intonation of the declarative phrase has a regular melody, close to a normal pattern of Spanish, except for a rise in the contour of f_0 at the end of the emission. This contour would correspond to an interrogative phrase. As for rhythm in the speech of this patient, interesting aspects are observed in figure 4.

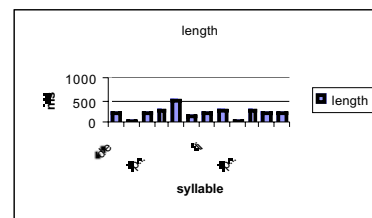


Figure 4. Analysis of the rhythm of a phrase of the patient LL. (Phrase: De ahí (pause) me metí (pause) a (pause) ventas).

In the analysis of the rhythm in the speech of LL pauses are observed between words and some lengthening in the final syllables of the words. This produces a general effect of halting speech. With respect to intonation one can say that LL evidences an alteration in the melodic pattern used: a final rise, a pattern associated with interrogative phrases, is observed in the production of declarative phrases. The alteration of rhythm manifests itself in the same way as in the previous case, with the difference that the interruption is between words and between syllables.

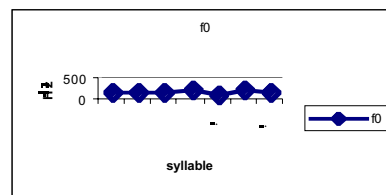


Figure 5. Analysis of the intonation of a phrase produced by the patient CR. (Phrase: Se me pega la lengua).

Case 3, CR: The speech of CR, in general presents an intonation considered within the normal pattern of the language as far as melodic variation goes. On the other hand, as we can observe, after the first peak of the contour, the fundamental frequency continues rising to fall sharply and ends in a rising fall, a pattern of some declarative and many exclamatory phrases in the variety of language studied.

With respect to rhythm, we notice halting speech, which is registered acoustically as unexpected pauses in the discourse. Natural hesitation pauses are also seen.

3. Summary and conclusions

The problems of dysprosody present in the three cases described include some difficulties in intonation, but, fundamentally, difficulties in rhythm, manifested as slowness of speech, segmentation of words, pauses between syllables and words or an abundance of silent pauses.

This study emphasizes the fact pointed out by Baum and Pell [1], that prosody is defined by multiple acoustic parameters such as rhythm and intonation. Moreover, as two patients show damage in the right hemisphere and one in the left hemisphere, this study suggests, as did Cancelliere and Kertesz [4], Baum and Pell 1999 [1], and Van Lancker and Sidtis [10], that there may be bilateral control of some aspects of linguistic prosody.

It is also important to point out that in the three patients the vascular cerebral damage extended to sub-cortical regions, which means that the relationship of sub-cortical areas with linguistic prosody cannot be discounted. Finally, the presence of prosodic problems in association with damage in anterior and posterior regions is evidence against the models that propose that the organization of language in the left hemisphere is parallel to the organization of prosody in the right.

4. References

- [1] Baum, S.; Pell, M., 1999. The neural basis of prosody: Insights from lesion studies and neuroimaging. *Aphasiology*, vol. 13, N° 8, 581-608.
- [2] Blumstein, S.; Cooper W. 1974. Hemispheric processing of intonation contours. *Cortex*, 10, 146-158.
- [3] Bradvik, B.; Dravins, C.; Holtas., S.; Rosen, I.; Ryding, E.; Ingvar., D., 1991. Disturbances of speech prosody following right hemisphere infarcts. *Acta Neurologica Scandinavica*, 84, 114-126.
- [4] Cancelliere, A.; Kertesz, A., 1990. Lesion localization in acquired deficits of emotional expression and comprehension. *Brain and Cognition*, 13, 133-147.
- [5] Fromkin, V., 1988. The state of brain/language research. In F. Plum (Ed.), *Language, communication and the brain*. NY: Raven Press
- [6] Klouda, G.; Robin, D.; Graff-Radford, N.; Cooper, W., 1998. The role of callosal connections in speech prosody. *Brain and Language*, 35, 154-171.
- [7] Ross, E., 1981. The aprosodias. Functional-anatomic organization of the affective components of language in the right hemisphere. *Archives of Neurology*, 38, 561-569.
- [8] Ross, E.; Mesulam, M., 1979. Dominant language functions of the right hemisphere?: Prosody and emotional gesturing. *Archives of Neurology*, 36, 144-149.
- [9] Van Lancker, D.; 1980. Cerebral lateralization of pitch cues in the linguistic signal. *International Journal of Human Communication*, 13, 227-277.
- [10] Van Lancker, D.; Sidtis, J.J., 1992. The identification of affective-prosodic stimuli by left- and right-hemisphere-damaged subjects: all errors are not created equal. *Journal of Speech and Hearing Research*, 35, 963-970.