

MUCOSAL WAVE MAGNITUDE: PRESENCE, EXTENT, AND SYMMETRY IN NORMOPHONIC SPEAKERS

Heather S. Shaw, Dimitar D. Deliyski

Department of Communication Sciences and Disorders, University of South Carolina, Columbia, South Carolina, USA

Abstract: Visualization of the vocal fold structure and function is imperative for accurate diagnoses and optimal treatment for persons with voice disorders. With the advent of commercial High-Speed Videendoscopy (HSV) systems, an increased amount of variation has been appreciated in the diagnostically relevant features of mucosal wave presence, magnitude, and symmetry. This study presents findings from the assessment of mucosal wave from stroboscopy, HSV playback, mucosal wave playback, and mucosal wave kymography playback. The results from this study demonstrate the prevalence of features of 'atypical' mucosal wave during modal productions of /i/ by normophonic persons. Utilizing modal and pressed phonations, an increased understanding of the effect of medial compression and increased subglottal pressure on mucosal wave was realized.

I. INTRODUCTION

One diagnostically significant feature of vocal fold vibration is the mucosal wave. The mucosal wave is the propagation of the epithelium and superficial layer of the lamina propria from the inferior to the superior surface of the vocal folds during phonation. A typical mucosal wave, as viewed through stroboscopy, should travel one-half of the width of the superior surface of the vocal fold during modal phonation [1]. The mucosal wave of vocal fold vibration is an accepted indicator of tension and pliability of the vocal fold tissue. The mucosal wave is usually reduced during high pitch phonations due to the excessive tension on the tissues. A reduced mucosal wave during modal phonation signifies stiffness, which may result from a lesion, edema, or scar. Conversely, a larger than normal mucosal wave signifies flaccidity of the laryngeal musculature underlying the vocal fold tissue, possibly indicating paresis or muscle atrophy due to aging. Thus, the importance of assessing mucosal wave during functional evaluations and for medical diagnoses is evident. For example, mucosal wave has been the sole feature of vocal fold vibration that could provide visual information upon which cysts and polyps could be differentiated [2].

The characteristics of normal mucosal waves have been investigated via stroboscopy. Multiple research articles have included mucosal wave as a dependent variable to answer various questions regarding normal and pathological vocal fold movement. Two main areas of research have investigated the impact of vocal fold

elongation, such as that seen in high frequency productions, and the impact of variations in subglottal pressure on mucosal wave magnitude and velocity.

Of interest is a conclusion regarding the typicality of lateral phase of mucosal wave symmetry in normophonic speakers in [3]. The results of reviewing fifty-seven videostroboscopic laryngeal examinations indicated that asymmetry was appreciated in 10.5% of normophonic participants during modal and falsetto phonations and in 36.5% of participants during falsetto phonations only. The conclusion was that the degree of magnitude and not merely presence of asymmetry should be considered the diagnostically significant feature. This conclusion leads to the necessity of further investigation of the symmetry and magnitude of mucosal waves.

The findings of a prevalent 'normal' amount of asymmetry may lead to an increase in over-diagnoses of laryngeal pathology, unless the typicality of variation is understood. Additionally, there is a possibility that symmetrical mucosal waves with supposed atypical magnitude may be present in persons with and without laryngeal pathologies. This finding would modify the conclusions from [3,4]. Given the prevalence of asymmetry seen in stroboscopic images and the increased amount of laryngeal dynamics visible through HSV, it is intuitive that an even larger population of normophonic speakers would have apparent variations in mucosal wave as viewed through HSV in comparison to stroboscopy.

Preliminary studies of the horizontal and vertical displacements, velocity, and vertical phase of the mucosal wave have been accomplished utilizing excised canine larynges [5,6,7]. The results are commensurate with the findings from in vivo human stroboscopic studies of mucosal wave. No further investigations of the typicality of variation in mucosal magnitude or symmetry have been published.

The purpose of this research was to investigate the normality of variation of mucosal wave presence, magnitude, and symmetry and to compare modal and pressed phonation across these features. The specific research questions were:

1. What is the variation in mucosal wave magnitude for normophonic speakers?
2. What degree of mucosal wave magnitude asymmetry can be appreciated in normophonic speakers?
3. How do the features of mucosal wave compare across modal and pressed phonations?

II. METHODOLOGY

Participants: Fifty-two vocally normal participants ranging in age from 18-65 years old were recruited from Columbia, SC and Charlotte, NC. Twenty-four male and twenty-eight female participants were divided among three age ranges from 18-33, 34-49, and 50-65. The data collection, storage, and use were in accordance with human subjects regulations. The data for this study was recorded at Presbyterian Hospital's specialized voice center in Charlotte, NC. The speech-language pathologists involved with data collection were specifically trained in voice. During the process of accepting participation in the study through the informed consent form, the participants completed a short medical and voice history, as well as a modified voice quality self-assessment. Speech-language pathologists utilized the history, self-assessment, and perceptual judgment to determine vocal normality.

Instrumentation and Procedures: Data collected for this study included: information from case history reports, stroboscopy, and high-speed videoendoscopy (HSV). Data collection from methods routinely used in the clinic and those that are new, allowed for a comparison between assessment methods. Data collection occurred in quiet rooms typically employed for assessment of voice clients in the hospital clinic.

Endoscopy and Stroboscopy: Standard clinical procedures were utilized for endoscopy and stroboscopy. The locating of the vocal folds and the initial phonation were conducted with continuous light. The stroboscopic light was used to capture phonation at three different pitch levels, habitual, low, and high, held at a near-constant intensity. The participants were asked to phonate at their habitual loudness while varying their pitch over samples. This allowed both intensity and frequency to be controlled for during each sample. A Kay Elemetrics Rhino-Laryngeal Stroboscopic System Model 9100B coupled to a 70-degree rigid endoscope was used. A laryngeal contact microphone was utilized to track vocal fold vibratory frequency.

High-Speed Videoendoscopy: Kay Elemetrics High-Speed Video System Model 9700 equipped with a camera that captures at 2000 frames per second (fps) with 120 x 256 pixel resolution was utilized. High-speed cameras require an intense light source for visualization of the vocal folds to be realized. A 70-degree rigid endoscope (Kay Elemetrics Model 9106), the same as that used in stroboscopy and a 300 W constant Xenon light sources (Kay Elemetrics Model 7152) were coupled with the system. The recording of HSV was synchronized with the acoustic recording, captured via a head-mount condenser microphone, to allow for comparisons between physical and acoustic events. Participants were instructed to phonate /i/ at habitual pitch and during pressed

phonation. To achieve pressed phonation, participants were asked to phonate "as if lifting a heavy box". Additionally, auditory examples of pressed phonation were provided.

Image Processing: Image processing included: motion compensation [8] and removal of reflection spots. These pre-processing techniques allowed for valid and accurate results from the kymographic playbacks. The compensation techniques were necessary to secure that anatomical structures subjected to kymography are time-aligned. It has been noted that if endoscope motion is unaccounted for it may affect the validity of the data [9]. The image processing techniques allowed for the evaluation of mucosal wave from the visual image.

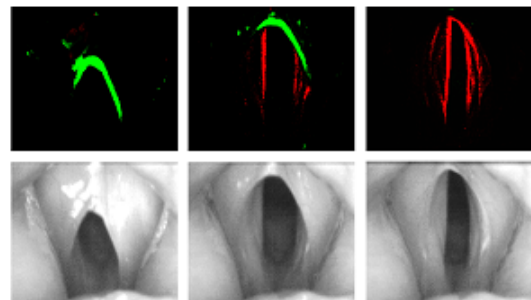


Fig. 1. Frames of Mucosal Wave (MW) playback (top) at different phases of the intra-glottal cycle and the corresponding HSV frames (bottom). The opening phase velocity on the MW images is encoded in shades of green, and the closing phase velocity is displayed in red.

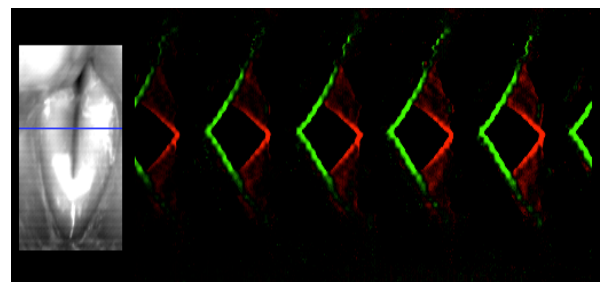


Fig. 2. Mucosal Wave Kymography (MKG) of consecutive glottal cycles during sustained phonation. The mucosal wave extent appears as a double edge during the closing phase.

Images were obtained using both stroboscopy and HSV. From stroboscopy, one image, the stroboscopy playback was rated. Stroboscopy provides a view of mucosal wave without true cycle-to-cycle information. From HSV, three playbacks were rated: the high-speed videoendoscopy playback, the mucosal wave (MW) playback, and the mucosal wave kymography (MKG) playback. HSV playback was defined as the typical

playback of the recording after motion compensation. The HSV playback provided a view of mucosal wave, which allowed for the visualization of true cycle-to-cycle information. Playback of the image with the mucosal wave highlighted in green for opening phase and red for closing phase was defined as MW playback (Fig. 1). The MW playback utilized velocity, encoded as intensity, to highlight the medial edges of the vocal folds and possibly provide easier magnitude ratings. The image from the mucosal wave playback presented as a movie from posterior to anterior was termed MKG playback. The MKG playback provides a view in which mucosal wave propagation and magnitude variations in the time domain may be more easily judged (Fig. 2).

Visual Perceptual Judgments: The motion images obtained from the fifty-two participants were visually evaluated and rated for specific features of the mucosal wave by two voice specialist. Images from fifty-two participants in four different views for two modes of phonation amounted to 394 images that were rated. In addition, 20% of the images were randomly repeated to obtain intra-rater reliability. Therefore, a total of 473 images were judged for features of mucosal wave.

Mucosal wave magnitude was rated, separately for the left and right vocal folds, on a six-point scale, with 0=absent, 1=severely decreased, 2=moderately decreased, 3=typical, 4=moderately increased, and 5=severely increased. Presence of mucosal wave was understood if the magnitude was assigned a rate of 1-5. Mucosal wave asymmetry was calculated by the differences in magnitude ratings. If the ratings of the left versus right mucosal wave magnitude differed, then the mucosal wave magnitude was considered asymmetrical. Mild asymmetry was characterized by a rating difference of one-point, moderate asymmetry by a difference of two-points, severe asymmetry by a difference of three-points, and profound asymmetry by a difference of four or more points.

III. RESULTS

The results for bilateral presence of mucosal wave, mucosal wave magnitude of the right and left vocal folds, and symmetry of mucosal wave magnitude are displayed in Tables 1-3, respectively.

	Strobe	HSV	MW	MKG
Habitual	79	72	66	65
Pressed		79	88	71

Table 1. Mean percent of recordings rated as having present mucosal wave bilaterally.

	Rating	Strobe	HSV	MW	MKG
Right	Typical	24	14	14.5	13
	Decreased	61	49	58	55
	Increased	5	4	2	2
Left	Typical	32	15	17	10.5
	Decreased	60	39	58	50
	Increased	5	5	3	2

Table 2. Mean percent of habitual phonation recordings rated as having typical, decreased, or increased mucosal wave magnitude for the right and left vocal folds.

	Rating	HSV	MW	MKG
Right	Typical	14	16	15
	Decreased	40	58	53
	Increased	13	4	26
Left	Typical	20	25	16
	Decreased	45	58	50
	Increased	11	4	2

Table 3. Mean percent of pressed phonation recordings rated as having typical, decreased, or increased mucosal wave magnitude for the right and left vocal folds.

	Rating	Strobe	HSV	MW	MKG
Habitual	Asymmetrical	24	27	21	21
	(Mild)	(7)	(23)	(19)	(18)
Pressed	Asymmetrical		39	37	21
	(Mild)		(39)	(33)	(19)

Table 4. Mean percent of recordings rated as displaying any asymmetry of mucosal wave magnitude, and mean percent of recordings rated as displaying only mild asymmetry of mucosal wave magnitude.

Intra-rater reliability was judged high with a mean agreement of 94.8 and 93.8% for raters 1 and 2, respectively. Inter-rater reliability was similarly high with percent agreement within one scalar level of 82, 88, 91, and 73% for HSV, MW, MKG, and stroboscopy. Due to these results, the mean ratings were reported for presence, magnitude, and symmetry.

IV. DISCUSSION

Mucosal wave absence was noted for at least 22% of vocal fold vibration samples from normophonic speakers across all displays, as seen in Table 1. Whether the playback viewed was kymographic or not appeared to decrease the ratings of presence from habitual phonation samples by at least 8%. Ratings of pressed phonation demonstrated an increase in likelihood of allowing for the visualization of mucosal wave. The limitation of 2000 fps capturing of the HSV images can help to explain the absence of mucosal wave noted via HSV-derived playbacks. However, a similar absence of mucosal wave was noted via stroboscopy.

The narrow definition of mucosal wave used for this experiment was inclusive only of the differential between the lower and upper margins of the vocal fold. Since ratings of absent mucosal wave are not thought to be typical even with mild voice disorders, it is apparent that clinicians are utilizing additional visual features to rate mucosal wave. It is probable that clinicians are also utilizing the vertical motion of the surface propagation. Alternatively, it is possible that ratings of mucosal wave are confounded with ratings of glottal width or amplitude of vocal fold vibration.

Mucosal wave magnitude was overall reduced for ratings from HSV and HSV-derived playbacks, as seen in Table 2 and 3. It is likely that the norm for stroboscopy does not apply to HSV. The capture rate of the commercially available HSV camera, of 2000 fps was not sufficient to provide multiple samples within the closing phase of vibration for persons with F_0 above 200 Hz. This insufficient sampling may reduce the perception of mucosal waves as well as reduce their perceived magnitude. However, a significant number of recordings were rated as exhibiting decreased magnitude through stroboscopy.

Mucosal wave asymmetry of vocal fold vibration was realized in a more than one-fifth of the normophonic participants for habitual phonation, as seen in Table 4. Differences between pressed and habitual phonations were less evident during the MKG playback, than during HSV and MW playbacks. All of the asymmetries, from HSV-derived techniques, were rated as mild or moderate. That is, the vocal folds did not vary more than two points in magnitude. The magnitude of asymmetry may be a future guideline for assessment. The results of this study are consistent with previously reported results from stroboscopy [4] in that mucosal wave asymmetry was perceived in normophonic speakers. However, an increased percent of asymmetries were perceived in this study for all playbacks. The asymmetry of mucosal wave magnitude via the HSV playback was consistently increased in comparison to the other playbacks for both habitual and pressed phonations.

V. CONCLUSION

The results of this study reinforce the presence of asymmetrical mucosal waves in the vocal fold vibration of normophonic speakers. This asymmetry was noted in both pressed and modal productions. Additionally, 'atypical' findings were abundant for mucosal wave magnitude. These findings should be referred to when determining the abnormality of mucosal wave variations during clinical visualization procedures. The variation of ratings across the HSV-derived playbacks demonstrates the strength of utilizing different views providing a balance between specificity and sensitivity. Thus, the HSV-derived playbacks should be used as an ensemble to maximize the benefit of visualization. A major conclusion of this investigation is the finding that 2000 fps is insufficient to record the intra-cycle information necessary to assess features of mucosal wave.

REFERENCES

- [1] M. Hirano, and D. Bless, *Videostroboscopic examination of the larynx*. San Diego, CA: Singular Publishing Group, 1993.
- [2] J.A. Shohet, M.S. Courey, M.A. Scott, and R.H. Ossoff, "Value of videostroboscopic parameters in differentiating true vocal fold cysts from polyps," *Laryngoscope*, vol. 106(1), 19-26, 1996.
- [3] C.M. Haben, K. Kost, and G. Papagiannis, "Mucosal wave asymmetries in the clinical voice laboratory," *Journal of Otolaryngology*, vol. 31(5), 275-280, 2002.
- [4] C.M. Haben, K. Kost, and G. Papagiannis, "Lateral phase mucosal wave asymmetries in the clinical voice laboratory," *Journal of Voice*, vol.17 (1), 3-11, 2003.
- [5] D.A. Berry, D.W. Montequin, and N. Tayama, "High-speed digital imaging of the medial surface of the vocal folds," *Journal of the Acoustical Society of America*, vol. 110 (5), 2539-2547, 2001.
- [6] S.H. Sloan, G.S. Berke, B.R. Gerratt, J. Kreiman, and M. Ye, "Determination of vocal fold mucosal wave velocity in an in vivo canine model," *Laryngoscope*, vol. 103, 947-953, 1993.
- [7] I.R. Titze, J.J. Jiang, and T.Y. Hsiao, "Measurement of mucosal wave-propagation and vertical phase differences in vocal folds vibration," *Annals of Otology Rhinology and Laryngology*, vol. 102(1), 58-63, 1993.
- [8] D.D. Deliyski, "Endoscope motion compensation for Laryngeal High-Speed Videoendoscopy," *Journal of Voice*, vol. 19(3), 485-496, 2005.
- [9] D.D. Deliyski, and P.P. Petrushev, "Methods for Objective Assessment of High-Speed Videoendoscopy," *Proceedings: 6th International Conference: Advances in Quantitative Laryngology, Voice and Speech Research AQL-2003, Hamburg, Germany, 28, 1-16, 2003.*